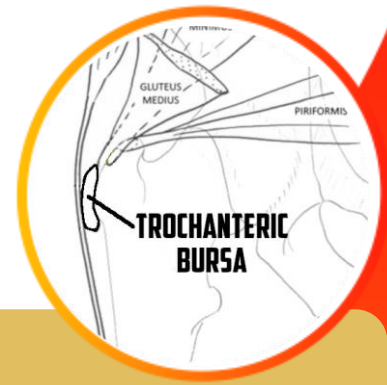


Greater Trochanteric Pain Syndrome



Key Points

- Common cause of lateral hip pain
- Historically termed 'Trochanteric Bursitis'
- Seen in conjunction with gluteal tendinopathy
- Can be imaged with an MRI, ultrasound
- Treated with physical therapy and injections

Condition

- Commonly occurs within the subgluteus maximus bursa (trochanteric bursa)
- Can present acutely, however most cases are chronic
- Risk factors: knee arthritis, IT band syndrome, low back pain
- Typically occurs in conjunction with gluteus tendinopathy
- More common in women than men, peaks in fourth and sixth decades of life

Symptoms

- Lateral hip pain is most common
- Pain can radiate down the leg in to the gluteus
- Pain worsens with walking and going up and down the stairs
- Pain when sleeping on the affected side
- Tender on the outside hip bone (greater trochanter)

Treatment

- First line treatment is activity modification and physical therapy
- Oral or topical NSAIDS are often used for pain
- Weight loss can help with pain
- Bursa can be injected with corticosteroids or platelet rich plasma
- Rarely is surgical management necessary

